

Do “Anatomic” Distal Ulna Plating Systems Fit the Distal Ulna Without Causing Soft Tissue Impingement?

HAND

1–6

© The Author(s) 2020

Article reuse guidelines:

sagepub.com/journals-permissions

DOI: 10.1177/1558944720930302

journals.sagepub.com/home/HAN

Daniel A. Shaerf¹ , Woo Jin Chae², Reza Sharif-Razavian² ,
 Vasiliki Vardakastani², Angela E. Kedgley² ,
 and Maxim D. Horwitz³

Abstract

Background: Distal ulna fracture fixation plates commonly cause irritation, necessitating removal, due to the narrow area between the ulna articular cartilage and the extensor carpi ulnaris. This study defines the safe zone for plate application and determines whether wrist position affects risk of impingement. **Methods:** Four different distal ulna anatomic plates (Acumed, Medartis, Skeletal Dynamics, and Synthes) were applied to 12 cadaveric specimens. Safe zone size was measured in circumferential distance and angular arc. Impingement was examined in flexion and extension in neutral, pronation, and supination. **Results:** The distal ulna safe zone has dimensions of a 92° arc and perimeter circumference of 15 mm. Cumulative extensor carpi ulnaris (ECU) impingement occurred in 0% of the 6 simulated wrist/forearm positions for the Acumed plate, 22% for the Synthes plate, 31% for the Skeletal Dynamics plate, and 68% for the Medartis plate. Impingement was most common in supination. Likelihood of ECU impingement significantly decreased in the following order; Medartis > Skeletal Dynamics > Synthes > Acumed. **Conclusion:** The ECU tendon's mobility can cause impingement on ulnarly placed distal ulna plates. Intra-operative testing should be performed in supination. Take home points regarding each plate from the 4 different manufacturers: contouring of Medartis plates, when placed ulnarly, is mandatory. The Acumed plate impinged the least but is not designed for far-distal fractures. The Synthes plate is least bulky but not suitable for proximal fractures. The Skeletal Dynamics plate appeared the most versatile with a reduced incidence of impingement compared to other ulnarly based plates.

Keywords: safe zone, biomechanics, basic science, wrist, fracture/dislocation, diagnosis, surgery, specialty, tendon, basic science, wrist, anatomy, plate, ulna, extensor carpi ulnaris

Introduction

The distal ulna is commonly fractured alone or in combination with the distal radius. The majority of injuries to the distal ulna can be managed without surgical intervention. Fractures at or proximal to the base of the ulna styloid including the ulna neck, particularly when displaced, can result in a loss of the fixed point of rotation, leading to instability of the distal radioulnar joint (DRUJ).¹ This instability is notoriously difficult to control with nonoperative methods and mini-fragment plates are commonly indicated for these fractures.² Fixation of fractures in this region is further complicated by the surrounding soft tissue structures and the large articular surface of the ulna head leaving little space for plate application. Structures prone to irritation that need to be avoided include dorsally the extensor carpi ulnaris (ECU), distally the articular surface, volarly

the flexor carpi ulnaris (FCU), and ulnarly the dorsal branch of the ulnar nerve (DBUN).³ A narrow safe zone with an arc of 2 hours on the clockface has been defined to avoid irritation of the ECU and articular impingement;⁴ however, no wrist position was specified.

Many manufacturers have designed anatomic plates specifically for fractures of the distal ulna. Only 2 of these plating systems have been assessed previously for fit within the

¹London North West University Healthcare NHS Trust, Middlesex, UK

²Imperial College London, UK

³Chelsea and Westminster Hospital NHS Foundation Trust, London, UK

Corresponding Author:

Daniel A. Shaerf, Department of Trauma and Orthopaedics, London

North West University Healthcare NHS Trust, Uxbridge Road,

Middlesex UB1 3HW, UK.

Email: shaerf@gmail.com

safe zone.⁴ No study has looked at the relative fit, contouring and thickness of these anatomic plates. Furthermore, it has not been determined whether the safe zone changes in dimensions with movement of the wrist, or how the relationship between the DBUN and the aforementioned safe zone is defined.

This cadaveric study aimed to confirm and compare the size and region of the safe zone for plate placement, document the position of the DBUN, review the plate profile prominence, and describe the likelihood of ECU/DBUN impingement of 4 commonly used anatomic distal ulna plates.

Materials and methods

After obtaining ethical approval, 12 cadaveric mid-humeral specimens were dissected using a standard ulnar approach using the intertendinous plane between the FCU and ECU by a fellowship trained wrist surgeon to expose the distal ulna while protecting and identifying the DBUN. The position of the nerve was documented with respect to the tip of the ulna styloid.

The tendon of ECU dorsally and the articular cartilage margin volarly were identified and marked with perpendicular Kirschner wires (K-wires) at the level of the proximal aspect of the ulna head articular cartilage. The circumferential distance on the surface of the ulna between these 2 K-wires was measured with a steel wire. The arc between the K-wires was calculated using calibrated analytic software (Figure 1) (ImageJ 1.52; National Institutes of Health, Bethesda, MD). The musculotendinous junctions of FCU, flexor carpi radialis (FCR), ECU and extensor carpi radialis longus/brevis (ECRL/B) were dissected and identified.

Four distal ulnar plates were tested: the Acu-Loc® volar distal ulna plate (Acumed, Hampshire, UK), the 2.5 mm APTUS® Tri-Lock distal ulna plate (Medartis, Derby, UK), the PROTEAN® distal ulna plate (Skeletal Dynamics, Miami, FL) and the 2 mm LCP® distal ulna plate (Synthes, West Chester, PA) (Figure 2). Each plate was applied to each specimen, in a random sequence, as per manufacturers' guidance in the position of best fit (Acumed plates were placed volarly, all other plates were placed ulnarly, Medartis plates were placed ulnarly, although they can be placed both ulnarly and volarly). Gentle compression was applied to the shaft of the plate with a single screw with no formal bending or excessive tightening to cause plate deformation. Plate prominence, defined as the distance between the bone and the superficial surface of the implant, was then measured in 3 zones on each plate (proximal, midpoint, and distal) using a digital Vernier caliper through unused screw holes to the most prominent part of the plate-screw construct. The plates were then securely fixed to the ulna with both proximal shaft and distal head locking screws after

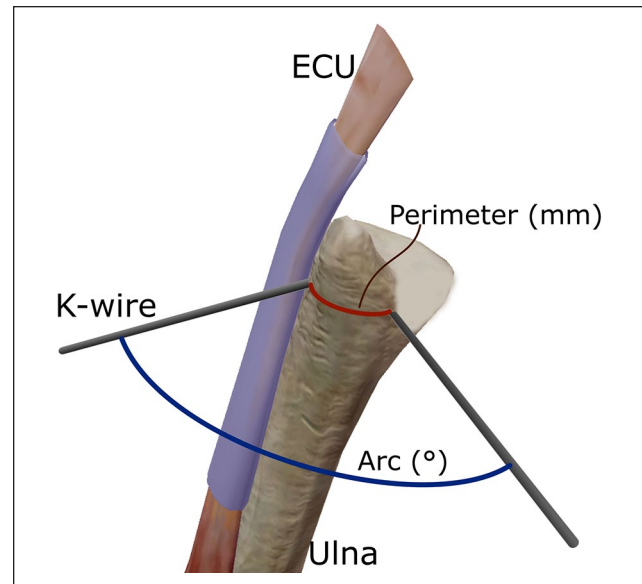


Figure 1. Diagrammatic representation of safe zone measurement; indicating the arc and perimeter measurements with respect to the ECU tendon and distal ulna articular surface. Note. ECU = extensor carpi ulnaris; K-wire = kirschner wires.

plate contouring, if necessary. Plate prominence measurements were then repeated.

A custom loading rig was used to recreate static postures. Rotation was secured with a proximally placed K-wire transfixing the radius and ulna in neutral, full passive pronation and full passive supination. Flexion and extension were simulated by applying a physiological axial load with masses⁵ attached using clamps sequentially to the FCR and FCU then ECRL/B and ECU musculotendinous junctions. Six static positions were recreated for each specimen combining flexion and extension in either neutral, pronation, or supination. Impingement was defined using a categorical scale to denote abutment (+), overlap (++), or no contact (-) with the DBUN (for ulnarly based subcutaneous plates) and the ECU tendon. All measurements and observations were independent, repeated, and undertaken by 2 independent observers. The results were analyzed using a 4-way log-linear analysis.

Results

The DBUN passed at or distal to the ulna styloid tip in all but 1 specimen at an average 5.4 mm (range: -5.0-24.0 mm; SD: 7.4 mm). The point at which the DBUN crossed the vertical axis in relation to the ulnar styloid was 1 (8%) Type 1 (proximal) nerve, 8 (67%) Type 2 (distal) nerves, and 3 (25%) Type 3 (at the styloid) nerves. The safe zone (between the ulna head articular cartilage volarly and the ECU dorsally) described an arc of 92° (range: 60°-123°, SD: 17°)




Figure 2. Commercially available volar locking plates used in this study. (a) Acu-Loc® volar distal ulna plate (Acumed, Hampshire, UK), (b) 2.5 mm APTUS® Tri-Lock distal ulna plate (Medartis, Derby, UK), (c) PROTEAN® distal ulna plate (Skeletal Dynamics, Miami, FL), and (d) 2 mm LCP® distal ulna plate (Synthes, West Chester, PA) (to scale).

and a perimeter circumference of 15 mm (range: 11-20 mm, SD: 2.6 mm).

Cumulative ECU impingement (defined as either abutment or tendon-plate overlap) occurred in 0% of the 6 simulated wrist/forearm positions for the Acumed plate, 22% for the Synthes plate, 31% for the Skeletal Dynamics plate, and 68% for the Medartis plate (Figure 3).

Cumulative DBUN impingement (either abutment or overlap) occurred in 2%, 35%, 24%, and 42% of the 6 simulated wrist/forearm positions for Acumed, Synthes, Skeletal Dynamics, and Medartis plates, respectively (Figure 4). Impingement occurred most commonly when the forearm was in supination (Figure 5). There was no tendency for increased or decreased impingement with wrist flexion or extension.

Baseline plate dimensions are shown in Table 1. No contouring was needed for Synthes, and Skeletal Dynamics plates. Infrequent and minimal contouring was required for Acumed plates in 2 specimens improving bone to plate surface depth by 5%. Medartis plates needed contouring in

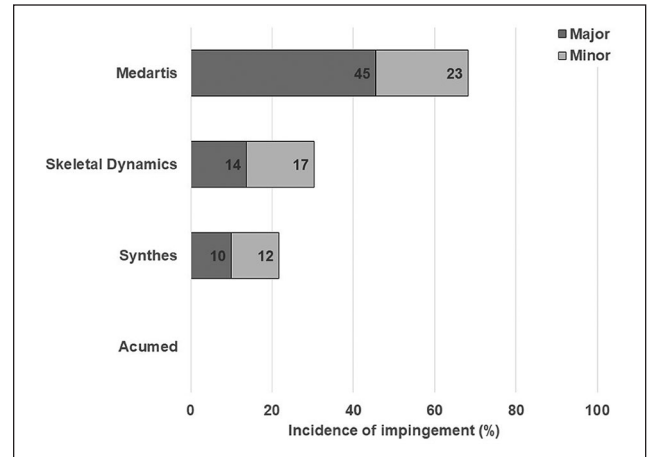


Figure 3. Incidence of tendon impingement, both major (overlapping plate) and minor (abutting plate), as a percentage of all trials (6 trials each of 12 specimens).

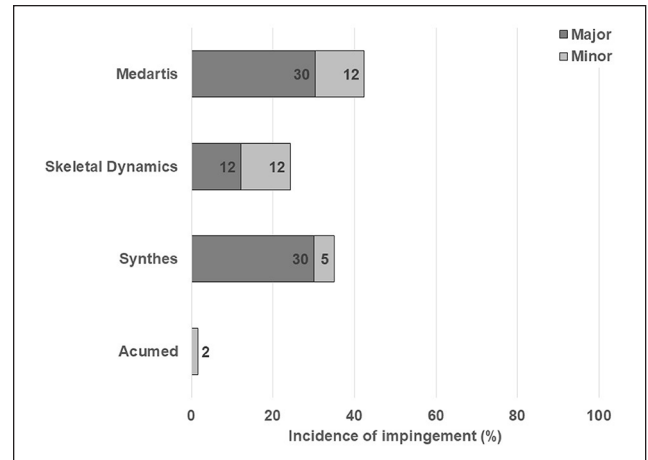


Figure 4. Incidence of nerve impingement, both major (overlapping plate) and minor (abutting plate), as a percentage of all trials (6 trials each of 12 specimens).

all specimens; after contouring, bone to plate surface depth decreased 37%, to a level similar to that which was present for the other plates. The Synthes plate was the thinnest and had the smallest profile (Figure 6).

Four-way log-linear analysis between all the measured variables showed that there were 2 significant second-order interactions. These occurred between plate type and tendon impingement, with $\chi^2(1) = 49.16, P = .035$, and between plate type and nerve impingement, with $\chi^2(1) = 55.38, P = .009$. A follow-up chi-squared test of association analysis (cross-tabulation) showed that there was a significant association between the type of plate and the likelihood of tendon impingement, linear likelihood chi-square, $\chi^2(1) = 73.1, P < .0001$, indicating that there is a linear decrease in the likelihood of tendon impingement in the following order: Medartis > Skeletal Dynamics >

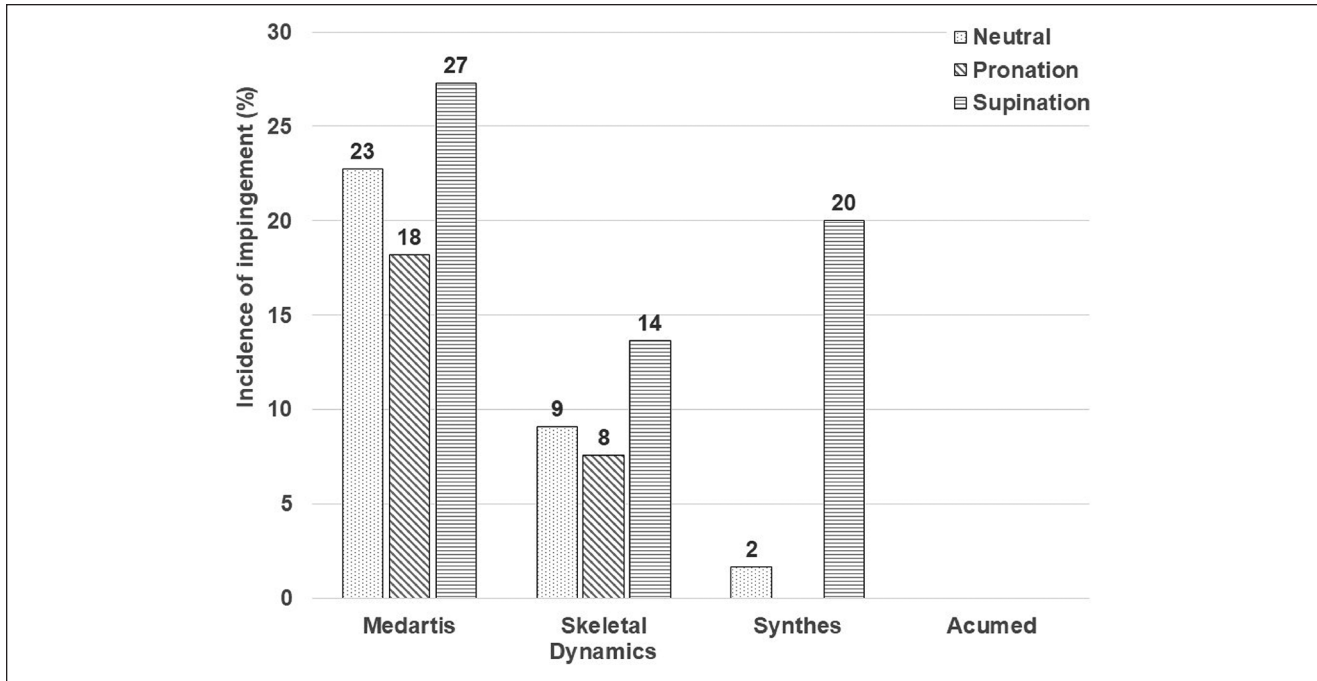


Figure 5. Incidence of tendon impingement categorized by wrist pronosupination position, as a percentage of all trials (6 trials each of 12 specimens).

Table 1. Distal Ulna Plate Dimensions.

	Width (mm)	Length (mm)	Thickness (mm)
Acumed	14	45-66 ^a	2
Medartis	16	46-67 ^a	1.6
Skeletal Dynamics	7.6	97.3 ^b	2
Synthes	5	46	1.3

^aTwo different plate lengths available.

^bPlate can be trimmed to size.

Synthes > Acumed. There was also a significant association between the type of plate and the likelihood of nerve impingement, $\chi^2(1) = 29.77, P < .0001$, indicating that there is a linear decrease in the likelihood of nerve impingement in the following order: Medartis > Synthes > Skeletal Dynamics > Acumed.

No other parameter interaction had a significant effect across the variables investigated. Using a fixed effect linear model, the occurrence of tendon impingement was dependent only on the plate type ($P < .001$); there was, however, a trend toward a difference with position of the forearm ($P = .07$).

Discussion

Fixation of distal ulna fractures is often performed following an assessment of stability of the DRUJ after fixation of

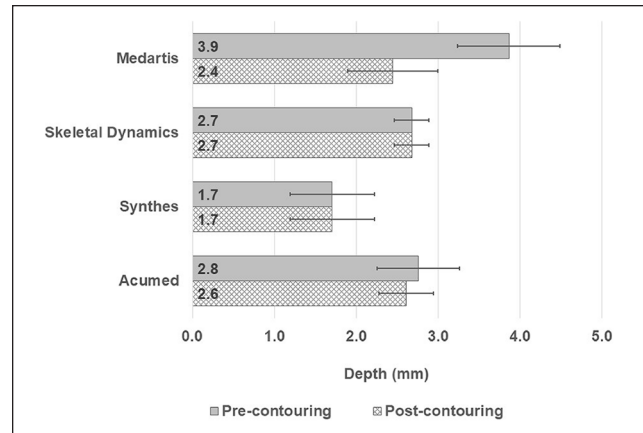


Figure 6. Bone to plate surface depth (distal) pre- and postcontouring means and standard deviations.

a concomitant distal radius fracture or after an isolated unstable solitary distal ulna fracture. Stability is most likely to be affected if the fracture lies proximal to the base of the ulna styloid and the deep attachment of the triangular fibrocartilage complex. The ulna is usually approached via the intertendinous plane between FCU and ECU, allowing extensile exposure of the distal ulna. The surrounding tendons, cutaneous nerves, and articular surface are in close proximity to where plates are applied. Being a subcutaneous bone, plates on the distal ulna are prone to prominence and irritation of the surrounding structures, necessitating

plate removal. Hazel et al. have previously defined, using 6 specimens, a cartilage free zone in the distal ulna, approximating 116° (SD: 6.8°) with a perimeter of 21.5 mm (SD: 3.3 mm). They also described the position of the ECU tendon as usually in the '1 o'clock' position on the right forearm (where 12 o'clock represents the ulna styloid). They concluded that a safe zone lay between 10 and 12 o'clock on the right and between 12 and 2 o'clock on the left. They further recommend that plate placement should be immediately volar to the ECU tendon; however, they make no comment on wrist position with relation to their safe zone.⁴

This study measured the safe zone, in 12 specimens, from the ECU dorsally to the articular cartilage volarly to represent a more accurate arc and perimeter. Furthermore, the wrist was mobilized, which demonstrated that the ECU tendon is a mobile structure even within its subsheath and has a tendency to change position with pronosupination.

The position of the DBUN has recently been examined by Uerpaiojkit et al., who described the position of the DBUN in 44 specimens. They found the DBUN crossed the vertical axis (a line passing from the ulnar border of the hand through the tip of the ulnar styloid and ulnar crest) at a mean of 10 mm distal to the ulna styloid tip. The most common path for the DBUN was volar to the vertical axis, swinging dorsally distal to the tip of the styloid in 77% of cases; they described this as a Type 2 nerve. Type 1 (9%) crossed the vertical axis proximal and Type 3 (14%) crossed at the styloid.⁶ These findings are similar to others who have examined the DBUN.^{7,8} Our study found similar trajectories of the DBUN with only 1 (8%) Type 1 nerve, 8 (67%) Type 2 nerves, and 3 (25%) Type 3 nerves.

No studies have previously looked at potential soft tissue complications around distal ulna plates. Das De et al. examined the soft tissue complications of ulna shortening osteotomy plates, which are placed more proximally, and found the need for plate removal more common in the volar group (33%) compared to the dorsal group (6%). However, the plates used volarly were thicker and longer compared to the dorsal plates.⁹ The plates used in the present study were ulnarly based plates, except for the Acumed plate, which was placed volarly.

Plate removal after ulna plating for trauma has not been studied; however, incidence of plate removal after ulnar shortening osteotomy varies between studies and plate location with volar plate placement—13%,¹⁰ 35%,¹¹ and 44%¹²; dorsal plate placement—29%¹³; and ulnar plate placement—32%.¹⁴ More recently, Elgammal and Rozee described a removal rate of only 11%.¹⁵ The thickness of ulna shortening plates are universally larger than anatomic plates specifically designed for distal ulna fractures.

There are some limitations to this study. We were only able to study plates from four manufacturers, although these are some of the most commonly used plates in the United Kingdom. It was not possible to truly standardize

the positioning of the different plate types as they are each designed to be placed in a slightly different anatomical position, each plate was placed as per the manufacturers' description in a position of best fit. During dissection, displacement of the DBUN and/or release of part of the ECU subsheath was possible; however, this was kept to a minimum using meticulous surgical technique. Placement of marking wires and measures of depth were performed perpendicular to the bony surface. We minimized angulation errors using multiple independent observers and a repeated-measures model. The study may have been underpowered to detect a true effect of wrist position on tendon and nerve impingement.

Conclusion

Take home points regarding each plate from 4 different manufacturers are as follows:

- If placing the Medartis plate ulnarly, then contouring is mandatory.
- The Acumed plate impinged the least but is not designed for far-distal fractures.
- The Synthes plate is least bulky but not suitable for more proximal fractures.
- The Skeletal Dynamics plate appeared the most versatile with a reduced incidence of impingement compared to other ulnarly based plates.

In conclusion, the area for plate placement around the distal ulna is narrow. The ECU tendon is a mobile structure and can cause impingement, thus intra-operative testing for impingement should be performed in supination.

Acknowledgments

Distal ulna plates were kindly provided without prejudice by manufacturers from Synthes, Medartis, Acumed, and Skeletal Dynamics.

Ethical Approval

Ethical approval for this study was obtained from the Imperial College Healthcare Tissue Bank Review Committee Approval 17/WA/0161 for Application R18047.

Statement of Human and Animal Rights

This article does not contain any studies with human or animal subjects.

Statement of Informed Consent

Informed consent was obtained when necessary.

Declaration of Conflicting Interests

The author(s) declared no potential conflicts of interest with respect to the research, authorship, and/or publication of this article.


Funding

The author(s) received no financial support for the research, authorship, and/or publication of this article.

ORCID iDs

Daniel A. Shaerf  <https://orcid.org/0000-0003-4607-9159>

Reza Sharif-Razavian  <https://orcid.org/0000-0003-1190-0816>

Angela E. Kedgley  <https://orcid.org/0000-0001-7282-6651>

References

1. Logan AJ, Lindau TR. The management of distal ulnar fractures in adults: a review of the literature and recommendations for treatment. *Strategies Trauma Limb Reconstr.* 2008;3(2):49-56.
2. Faierman E, Jupiter JB. The management of acute fractures involving the distal radio-ulnar joint and distal ulna. *Hand Clin.* 1998;14(2):213-229.
3. Richards TA, Deal DN. Distal ulna fractures. *J Hand Surg Am.* 2014;39(2):385-391.
4. Hazel A, Nemeth N, Bindra R. Anatomic considerations for plating of the distal ulna. *J Wrist Surg.* 2015;4(3):188-193.
5. Kobayashi M, Garcia-Elias M, Nagy L, et al. Axial loading induces rotation of the proximal carpal row bones around unique screw-displacement axes. *J Biomech.* 1997;30(11-12):1165-1167.
6. Uerpaiojkit C, Kittithamvongs P, Puthiwara D, et al. Surgical anatomy of the dorsal cutaneous branch of the ulnar nerve and its clinical significance in surgery at the ulnar side of the wrist. *J Hand Surg Eur Vol.* 2019;44(3):263-268.
7. Goto A, Kunihiro O, Murase T, et al. The dorsal cutaneous branch of the ulnar nerve: an anatomical study. *Hand Surg.* 2010;15(3):165-168.
8. Poublon AR, Kraan G, Lau SP, et al. Anatomical study of the dorsal cutaneous branch of the ulnar nerve (DCBUN) and its clinical relevance in TFCC repair. *J Plast Reconstr Aesthet Surg.* 2016;69(7):983-987.
9. Das De S, Johnsen PH, Wolfe SW. Soft tissue complications of dorsal versus volar plating for ulnar shortening osteotomy. *J Hand Surg Am.* 2015;40(5):928-933.
10. Ahsan ZS, Song Y, Yao J. Outcomes of ulnar shortening osteotomy fixed with a dynamic compression system. *J Hand Surg Am.* 2013;38(8):1520-1523.
11. Pomerance J. Plate removal after ulnar-shortening osteotomy. *J Hand Surg Am.* 2005;30(5):949-953.
12. Chen NC, Wolfe SW. Ulna shortening osteotomy using a compression device. *J Hand Surg Am.* 2003;28(1):88-93.
13. Megerle K, Hellmich S, Germann G, et al. Hardware location and clinical outcome in ulna shortening osteotomy. *Plast Reconstr Surg Glob Open.* 2015;3(10):e549.
14. Loh YC, Van Den Abbeele K, Stanley JK, et al. The results of ulnar shortening for ulnar impaction syndrome. *J Hand Surg Br.* 1999;24(3):316-320.
15. Elgammal A, Rozee B. Outcomes of the ulnar shortening osteotomy using a dynamic compression plate on the ulnar surface of the ulna. *J Wrist Surg.* 2018;7(4):344-349.